


RESEARCH

Open Access



Facial soft tissue response to maxillo-mandibular advancement in obstructive sleep apnea syndrome patients

Julio Cifuentes¹, Christian Teuber², Alfredo Gantz¹, Ariel Barrera¹, Gholamreza Danesh³, Nicolas Yanine¹ and Carsten Lippold^{4*} 

Abstract

Background: Facial profile soft tissue changes after orthognathic surgery are crucial for surgery success. This retrospective study evaluated soft tissue changes after maxillo-mandibular Advancement and counter clockwise rotation surgery in obstructive sleep apnea syndrome patients.

Methods: Thirty-seven obstructive sleep apnea syndrome patients (30 male, 7 female, mean age 35.8 years) whose underwent maxillo-mandibular-advancement and counter clockwise rotation surgery were studied after two intervals of time, presurgical, postsurgical and follow up (1–6 months and 1–5 years) using Dolphing Imaging Software. The soft tissue changes that were evaluated included Glabella, nasal projection, Subnasale, superior incisor, superior lip, inferior incisor, inferior lip, soft tissue B' point and soft tissue Pogonion. Points were measured from true vertical line on the horizontal plane according to Arnett soft tissue profile analysis. Wilcoxon test was applied for testing differences between T0 (pre surgical), T1 (1–6 months postsurgical) and T2 (1–5 years postsurgical).

Results: Cephalometric points changed to more aesthetic parameters. The largest advancements took place in the mandible, due to patients' anatomic characteristics and treatment planning, whose were measured at cephalometric points B' (9,05 mm) and Pog' (11,92 mm) at T0–T2. In all patients aesthetics goals were accomplished.

Conclusion: This study showed that maxillo-mandibular advancement and counter clockwise rotation surgery is an effective treatment for OSAS, with good aesthetic results.

Keywords: Obstructive sleep apnoea syndrome, Maxillo-Mandibular Advancement, Facial soft tissue change

Background

Obstructive sleep apnea syndrome (OSAS) is characterized by repetitive episodes of pharyngeal collapse with increased airflow resistance during sleep [1]. Risk factors include obesity, middle aged male gender, advanced age and an anatomically smaller upper-airway [1–7]. Up to 25% of adults represent signs and symptoms of OSAS, and approximately 10% of all adults have a moderate to severe level of OSAS [4, 5]. It is associated with higher rates of cardiovascular and cerebrovascular morbidity

and mortality as well. Continuous positive airway pressure (CPAP) therapy has been considered the reference standard treatment for OSAS. However, despite the potential success of CPAP, patient compliance represents a clear problem [8], causing them to seek surgical treatment alternatively. The goal of surgical treatment in OSAS is to enlarge the velo-oropharyngeal airway by anterior/lateral displacement of the soft tissues and musculature by maxillary, mandibular, and possibly genio-glossus advancement [2]. From a medical point of view there are two major rationales for surgery that need to be well understood at the time of surgical MMA planning [2]. The first rationale is “behavioral derangement,” which is normally due to excessive daytime sleepiness (EDS). Symptoms may include snoring, apneas, morning

* Correspondence: carstenlippold@yahoo.de

⁴Department of Orthodontics, Universitätsklinikum Münster, Albert-Schweitzer-Campus 1, Gebäude W30, Waldeyerstraße 30, 48149 Münster, Germany

Full list of author information is available at the end of the article



headaches, fatigue, day sleepiness, memory loss, irritability or poor work performance [3–5]. The second rationale is “pathophysiologic derangement,” which is, in part, cardiorespiratory in nature. Three important well-known physiological processes are involved in OSAS that predispose to these risks: hypoxemia, negative intrathoracic pressure, and disequilibrium of the autonomic nervous system [1–5].

It has been reported in literature that MMA has a high rate of success: beginning in the early 1980s, several studies reported improvement in polysomnographic parameters in patients treated with isolated mandibular advancement surgery [4, 5, 9–11]. However, by the mid-1980s, combined MMA was preferred over mandibular osteotomy alone to treat OSAS patients with normal maxillo-mandibular relationship to preserve the maxillo-mandibular relations, and due to the recognition of the physiologic etiology of OSAS, which is often caused by concomitant mandibular and maxillary deficiencies [12, 13].

Holty and Guillaminault determined in their systematic review and meta-analysis that MMA is an effective treatment for OSAS [5]. The mean apnea hypopnea index (AHI) decreased from 63.9 (severe sleep apnea) to 9.5 (mild sleep apnea) with a pooled surgical success rate of 86%. They also determined univariate predictors for surgical success for young age, lower preoperative AHI, and greater degree of maxillary advancement. To determine the success of performing MMA, Pirkbauer et al. [14] showed in a systematic review, that MMA therapy has good clinical results, even comparable to ventilation therapy for OSAS patients. Although MMA has been primarily recommended for patients with OSAS and significant maxillo-mandibular deficiency, it could also be advocated for the treatment of OSAS in patients with relatively mild maxillofacial abnormalities. It appeared that, despite the alteration of facial esthetics after MMA, more than 90% of the patients gave positive or neutral responses to their facial appearance after surgery [15].

As a large proportion of OSAS sufferers are mature adult males [4, 15], a number of patients requiring MMA surgery will present with a face showing signs of ageing, in particular skeletal atrophy, a sagging tip of the nose and hollow cheeks. Because MMA brings forward the skeletal structures of the midface and lower face complex and strains cutaneous soft tissues, the procedure can rejuvenate the patient’s appearance. Facial changes resulting from MMA are generally well received [14, 15]. Nevertheless, a number of patients find they are less attractive following the procedure. Li et al. found that 10% of their patients thought that they were less attractive [15]. These negative effects, which have also been described by other surgical teams, are nonetheless considered to be of secondary importance by patients compared with the benefits achieved by the surgery [1–5, 9–12].

More research is required into these “aesthetic failures” as a number of patients could refuse surgery to avoid the risk of facial deformity. This is especially true for young subjects with full faces or for women with finer soft tissues, which would not conceal their skeletal contours.

It has been demonstrated that during MMA, the soft tissues follow skeletal displacement to a large extent in the anteroposterior dimension [16–18]. To reduce the convexity of the upper lip, some surgeons systematically incorporate counter-clockwise rotation into the maxillo-mandibular complex during the advancement; but in our surgical team it is used due to the advancement of the mandible.

While soft tissue changes after orthognathic surgery have been studied for many years, little is known about the changes in facial appearance after MMA in patients with OSAS.

In our present retrospective study we performed a cephalometric analysis of soft tissue changes in a typical group of OSAS patients. The hypothesis in this study, was that

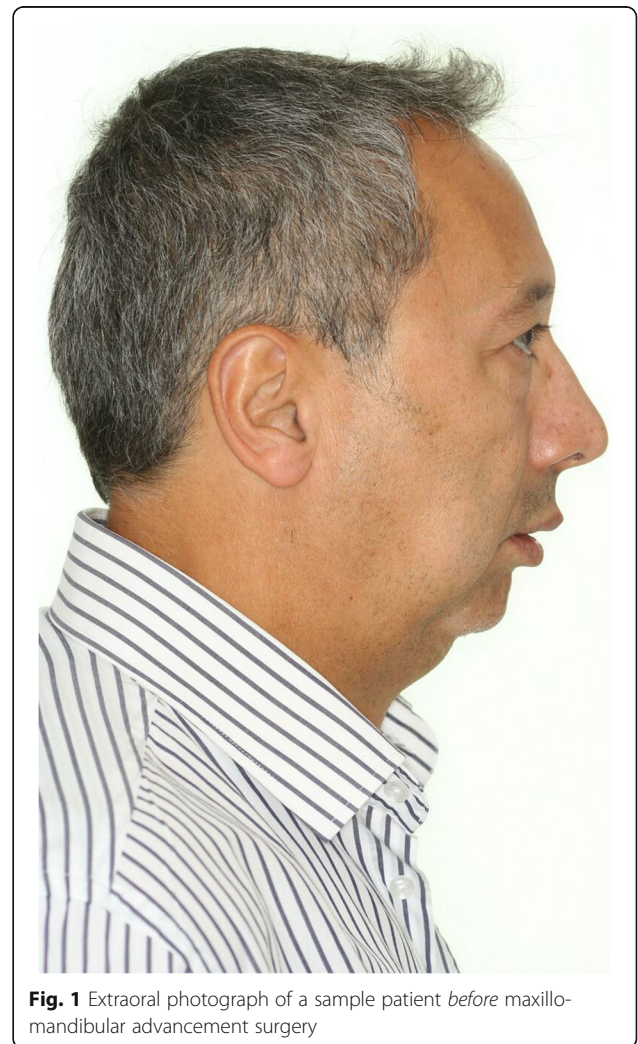

Fig. 1 Extraoral photograph of a sample patient before maxillo-mandibular advancement surgery

there are significant differences between the measured values at T0 and T1 and T0 and T2.

Methods

The study sample was compounded of 37 patients (30 males and 7 females) matching the inclusion and exclusion criteria of this retrospective analysis. The patients mean age were 35.8 years. At time of surgery, the youngest patient was 21.1 years old while the oldest patient was 56.2 years old. All OSAS patients were operated on by the same surgical team at the oral and maxillofacial unit (Clínica Alemana, Santiago, Chile) by maxillo-mandibular advancement and counter clockwise (CCW) rotation (Figs. 1, 2, 3 and 4).

All patients were treated in the same way with regard to preoperative, perioperative and postoperative care. Under general anesthesia a Le Fort I and segmental maxillary osteotomy was performed in addition to a bilateral sagittal osteotomy of the mandibular ramus and a mental osteotomy. The latter osteotomies were performed to allow maxillo-mandibular and chin advancement. Rigid internal fixation was performed with titanium plates (KLS – Martin and Osteomed). Four “L” miniplates were used in the maxilla, and four “straight” miniplates were used in the bilateral sagittal osteotomy (2.0 mm miniplates, with four 2.0 mm monocortical screws), to give more stability to the mandibular advancement with CCW Rotation. One genioplasty plate, “double Y shape,” was used in chin advancement. The movements of the double jaw orthognathic surgery, in

addition to chin advancement, were mainly counterclockwise to maxilla-mandibular advancement.

Inclusion criteria were all patients diagnosed with OSAS, skeletal class II, >18 years, who were treated with MMA and CCW rotation. In all patients with these skeletal characteristics we performed MMA with CCW rotation, because we can achieve an improved nasal airway, increased nasopharyngeal and oropharyngeal airway, normal chin projection and facial harmony.

Exclusion criteria included patients previously treated for maxillofacial deformities by other types of orthognathic surgery or orthodontics, facial trauma, systemic diseases and strokes not caused by OSAS.

To assess the soft tissue changes of the surgical procedure cephalometric radiographs were analysed. Radiographs were taken at T0 presurgical, T1 at a mean of 5.2 weeks after surgery, and T2 at a mean of 2.1 years after surgery. They were performed with a standard length marker of 100.0 mm at natural head posture with passive lips as described in the method by Arnett et al. [11], using a Ortophos XG 3D (Sirona, Bensheim, Germany). The imaging proportion used was 1:1, which was digitalized with Dolphin Imaging Version 11.7 Premium (Chatsworth, CA, USA). Based on the cephalometric soft tissue points described by Arnett et al. [11], a cephalometric analysis was performed (Figs. 5 and 6). Nine points (in both hard and soft tissues) were selected in relation to the true vertical line (TVL), which is a perpendicular line that passes through the subnasal point: glabella, nasal

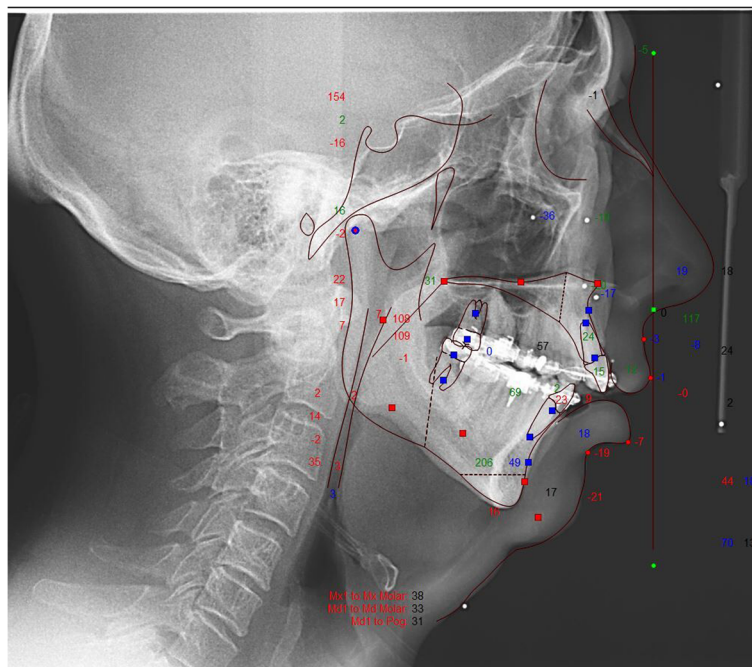


Fig. 2 Lateral cephalograph of a sample patient before maxillo-mandibular advancement surgery

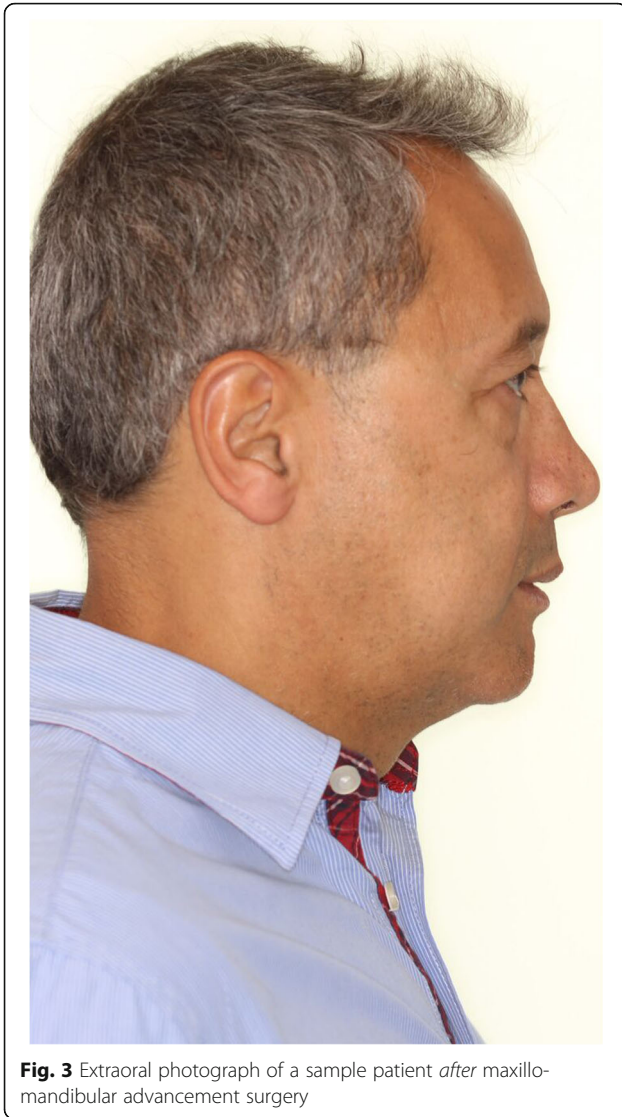


Fig. 3 Extraoral photograph of a sample patient after maxillo-mandibular advancement surgery

projection, upper lip anterior, upper incisor, inferior lip, inferior incisor, soft tissue B point, soft tissue pogonion. The distance measurements were carried out between the reference points perpendicular to the TVL. Figure 5 shows the basic principle of this analysis, the corresponding points and the true vertical line. Figure 6 is an example of the analysis. Statistical data analysis was performed with SPSS Version 18.0 statistical software (SPSS Inc., Chicago, IL, USA). Kolmogorov–Smirnov test was used for testing the normal distribution. The samples showed no normal distribution at T0, T1 and at T2. The null hypothesis in this study was, that there are no significant differences between the measured values at T0 and T1 and T0 and T2. To assess differences between T0 and T1 and T0 and T2 the Wilcoxon signed-rank test was applied.

Results

The results of the cephalometric analysis are shown in Table 1 as the mean and the standard deviation minimum and maximum values for T0, T1 and T2. The measurements were obtained in millimeters for each of the points evaluated in relation to the TVL for T0, T1 and T2. Positive values are for a position in front of the TVL, and negative values are for a posterior position. The statistical analysis with Wilcoxon test is shown in Table 2.

Discussion

Skeletal changes upon orthognathic surgery determine the soft tissue facial profile, which is observed by many surgeons as one of the parameters of successful treatment [11–21]. The main objective of MMA for OSAS patients is to cure the disease and decrease AHI values. Although the OSAS can be cured, aesthetics takes a fundamental role in defining a surgical success.

This study assessed the changes in facial profile after skeletal movements observed in patients diagnosed with OSAS. The aim was to describe variations of soft tissues between presurgical (T0) and two postsurgical evaluations (T1 and T2).

The response of the facial soft tissues after orthognathic surgery may be influenced by various factors, such as presurgical, surgical and postsurgical variables. Presurgical variables may include concurrent soft tissue deformities, nasal deformities, a degree of mandibular retrusion, previous trauma or maxillofacial surgeries, and thickness, as well as length and tone of the soft tissue overlying the area. Surgical variables may include a degree of dissection, edema or hematoma formation, an amount of bony resection, an amount of graft procedures, amount and direction of MMA movement, and surgical closure techniques. Postsurgical variables may include degree of bony resorption, weight gain or loss after surgery, relapse of bone segments, resultant soft tissue scarring, postoperative infection, and soft tissue stability [17].

Presurgical variables cannot be controlled; however, surgical and most of the postsurgical variables may be controlled to produce predictable results. Facial tissue changes after MMA and CCW rotation appear to be stable at 6–8 months after surgery [6, 7, 16–18, 20–22]. The evaluation of facial aesthetics must be performed at least 6 months after surgery to obtain reliable results. In this study, we observed patients who had at least 12 months postsurgery.

Upper lip variations shown in Table 1 demonstrate that edema can increase the upper lip's position from TVL up to 66% on the first 4–5 weeks postsurgery, but, as postsurgical time passes, so does the edema, and it finally stabilizes at 15.1% from the TVL, which is 0,22 mm. An inverse pattern occurs at nasal projection,

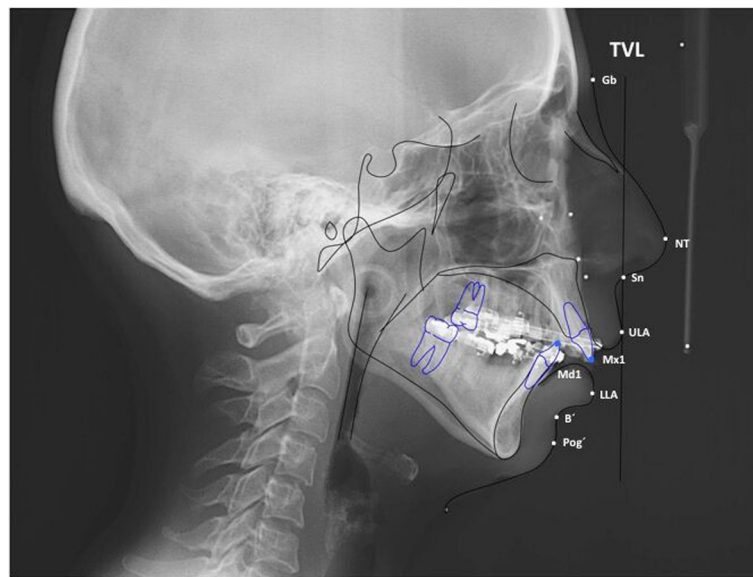


Fig. 6 Sample of a cephalometric radiograph of the lateral soft tissue facial analysis

8.7 mm) and the mandible (10.7–11.2 mm), but only a few studies have determined whether the patient truly accepted the aesthetic appearance. The studies of Li et al. [15, 19] revealed that soft tissue changes caused by MMA in their patient population appeared to result in a rejuvenation of the face. Ageing results in soft tissue descent with loss of lips and cheek prominence. MMA leads to skeletal expansion, which increases the soft tissue support with positive aesthetic effect, similar to the facelift procedure. Laxity of soft tissue and the facial thick envelope of the OSAS patients partially mask the effect of the skeletal advancement.

Arnett et al. [8, 24] have described in their studies normal aesthetic cephalometric guidelines, referring to the soft tissue cephalometric diagnosis. Therefore they measured patients in five different but interrelated areas. These areas were dentoskeletal factors, soft tissue structures, TVL Projection, Facial Length and Harmony Values. TVL projections are anteroposterior measurements of soft tissue and represent the sum of the dentoskeletal position plus the soft tissue thickness overlying that hard tissue landmark. The horizontal distance for each individual landmark, measured perpendicular to the TVL, is termed the landmark's absolute value. Although subnasale will frequently be coincident with anteroposterior positioning of the TVL, they are not synonymous. For example, the TVL must be moved forward in cases of maxillary retrusion [8].

The results of the soft tissue cephalometric analysis of Arnett et al. [8] are quite similar to the results of our study. They described aesthetic results for different cephalometric points in females and males. Our study did not describe the cephalometric points by gender due to a

smaller sample size and a small number of 7 female patients in comparison to 30 male patients. If we make a comparison between our results and Arnett et al. [8], they showed that the glabella was measured to be -8.5 mm in females and -8.0 mm in males; our study showed a measurement of -8.3 mm. The nasal projection measured at 16 mm for females and 17.4 mm for males; our study measured the nasal projection at 15.2 mm. The upper lip measurement was 3.7 mm for females and 3.3 mm for males; our study measured the upper lip to be 1.6 mm. The inferior lip measurement was 1.9 mm for females and 1.0 mm for males; our study measurement for the inferior lip was -2.8 mm. The B' point measurement was -5.3 mm for females and -7.1 mm for males; our study measured the B' to be -9 mm. In the same study the Pog' was measured to be -2.6 mm for females and -3.5 mm for males; in our study we measured -5.9 mm. Our aesthetic cephalometric measurements from soft tissues analysis were not as described by Arnett et al. [8], but quite similar. However, we need to consider that these patients had skeletal class II relationships, obstructive sleep apnea syndrome as a severe disease, and an average measure of the B' point and the Pog' of -18.1 mm and -17.8 mm, respectively.

According to the results of our study, there were no disproportionate postsurgery facial features, which otherwise could have affected social relationships and the quality of life.

Conclusions

The results of our study confirm maxillo-mandibular advancement as a valid treatment for obstructive sleep apnea syndrome in patients with normal facial proportions and skeletal class II. An accurate understanding of

Table 1 Descriptive statistics of the patients sample (mean, SD, minimum, maximum)

		Descriptive Statistics				
		N	Mean	SD	Minimum	Maximum
T0	Gb	37	-6.811	3.2900	-15.0	-2.0
	NT	37	17.216	2.0835	11.0	21.0
	Sn	37	0.000	0.0000	0.0	0.0
	ULa	37	1.432	2.2304	-2.0	6.0
	Mx1	37	-12.865	7.2156	-20.0	25.0
	Mn1	37	-5.459	2.9401	-11.0	0.0
	LLa	37	-19.784	3.7575	-26.0	-13.0
	B'	37	-18.054	4.0411	-26.0	-6.0
	Pog'	37	-17.784	5.5183	-30.0	-4.0
T1	Gb	37	-10.000	3.4721	-20.0	-5.0
	NT	37	13.324	1.9868	8.0	18.0
	Sn	37	0.000	0.0000	0.0	0.0
	ULa	37	2.378	2.9660	-4.0	9.0
	Mx1	37	-17.216	3.2586	-25.0	-9.0
	Mn1	37	-3.703	2.7169	-10.0	2.0
	LLa	37	-19.946	3.4637	-29.0	-11.0
	B'	37	-11.216	3.7129	-20.0	0.0
	Pog'	37	-9.622	4.2645	-18.0	3.0
T2	Gb	37	-8.324	4.2495	-22.0	-1.0
	NT	37	15.243	2.0194	10.0	20.0
	Sn	37	0.000	0.0000	0.0	0.0
	ULa	37	1.649	2.7408	-4.0	6.0
	Mx1	37	-12.297	4.7950	-20.0	9.0
	Mn1	37	-2.757	3.2094	-10.0	4.0
	LLa	37	-15.595	3.1838	-22.0	-7.0
	B'	37	-9.000	4.2426	-18.0	-1.0
	Pog'	37	-5.865	4.5532	-17.0	3.0

Mean, standard deviation, minimum and maximum values in millimeters of the measurements for T0 (presurgical), T1 (1–6 months postsurgery) and T2 (6 months to 5 years after surgery) between the cephalometric points and the TVL

Abbreviations: Gb Glabella, NT Nasal Tip, Sn Subnasale, ULa Upper Lip Anterior, Mx1 Upper Central Incisor Edge, LLa Lower Lip anterior, Mn1 Lower Central Incisor Edge, B' Soft Tissue B-Point, Pog' Pogonion Mollie

Table 2 Wilcoxon test at T0–T1 and T0–T2 for the patient sample

Statistics Wilcoxon test									
	Sn–Gb	Sn–NT	Sn–Sn	Sn–ULA	Sn–Mx1	Sn–LLA	Sn–Md1	Sn–B'	Sn–Pog'
T0–T1	-4.31	-5.24	0.000	-1.67	-4.49	-3.05	-0.20	-5.14	-5.15
p-value asymptotic significance (2-sides)	<0.001	<0.001	1.000	0.094	<0.001	0.002	0.837	<0.001	<0.001
T0–T2	-2.31	-4.35	0.000	-0.54	-2.15	-3.94	-4.78	-5.16	-5.24
p-value asymptotic significance (2-sides)	0.021	<0.001	1.000	0.586	0.032	<0.001	<0.001	<0.001	<0.001

The cephalometric points' movement in millimeters (mm) and the proportion of movement (%) between the same points in T0 (presurgical), T1 (1–6 months postsurgery) and T2 (6 months to 5 years after surgery)

the soft tissue response is necessary for treatment planning, prediction and patient education.

Abbreviations

MMA: Maxillo- mandibular advancement; OSAS: Obstructive sleep apnea syndrome; TVL: True vertical line

Acknowledgements

The authors want to thank the Open Publication Fund of the University of Muenster for their support.

Funding

The authors declare, that they received funding from the open access publication fund of the University of Münster.

Availability of data and materials

The data will not be shared.

Authors' contributions

JC, CT, AG, NY, GD and CL contributed to the conception, design and coordination of the study. CT, NY and AB made substantial contributions to the acquisition of data. JC, AG, AB and NY performed the operations of the patient sample. GD, CT, AB and CL contributed to the data analysis and made the statistical analysis; CT, NY and JC made the literature research for the study. JC, CT, AG and CL drafted the manuscript. JC, AG and CT created and layouted the figures and tables. All authors read and approved the final manuscript. All authors read and approved the final manuscript and take responsibility for the integrity and accuracy of any part of the study.

Competing interests

The authors declare, that they have no competing interests.

Consent for publication

The patients gave their informed consent for publication. All authors gave their consent for publication.

Ethics approval and consent to participate

The present study was approved by the Comité Etico Científico de Facultad de Medicina, Clínica Alemana de Santiago, Universidad del Desarrollo, Centro de Bioética, Comité Etico Científico, Chile (ref-no 2016-38). All patients gave their written informed consent to participate in this study.

Publisher's Note

Springer Nature remains neutral with regard to jurisdictional claims in published maps and institutional affiliations.

Author details

¹Department of Oral and Maxillofacial Surgery, Clínica Alemana, Av Vitacura 5951, Vitacura, Santiago, Chile. ²Department of Oral and Maxillofacial Surgery, Pontificia Universidad Católica de Chile, Av Libertador Bernardo O'Higgins 340, Santiago, Chile. ³Department of Orthodontics, Faculty of Health, University Witten/Herdecke, Alfred-Herrhausen-Strasse 44, 58455 Witten, Germany. ⁴Department of Orthodontics, Universitätsklinikum Münster, Albert-Schweitzer-Campus 1, Gebäude W30, Waldeyerstraße 30, 48149 Münster, Germany.

Received: 30 November 2016 Accepted: 15 June 2017

Published online: 23 June 2017

References

- Guilleminault C, Tilkian A, Dement WC. The sleep apnea syndromes. *Annu Rev Med.* 1976;27:465–84.
- Schendel S, Powell N, Jacobson R. Maxillary, mandibular, and chin advancement: treatment planning based on airway anatomy in obstructive sleep apnea. *J Oral Maxillofac Surg.* 2011;69:663–76.
- National Commission on Sleep Disorders Research. Report of the National Commission on Sleep Disorders Research. Superintendent of Documents, US Government Printing Office, Washington, DC; 1992 (Department of Health and Human Services Publication 92).
- Caples SM, Rowley JA, Prinsell JR, Pallanch JF, Elamin MB, Katz SG, et al. Surgical modifications of the upper airway for obstructive sleep apnea in adults: a systematic review and meta-analysis. *Sleep Med Rev.* 2010;33:1396–407.
- Holty JE, Guilleminault C. Maxillomandibular advancement for the treatment of obstructive sleep apnea: a systematic review and meta-analysis. *Sleep Med Rev.* 2010;14:287–97.
- Conley RS, Boyd SB. Facial soft tissue changes following maxillomandibular advancement for treatment of obstructive sleep apnea. *J Oral Maxillofac Surg.* 2007;65:1332–40.
- Gerbino G, Bianchi FA, Verzé L, Ramieri G. Soft tissue changes after maxillo-mandibular advancement in OSAS patients: A three-dimensional study. *J Craniomaxillofac Surg.* 2014;42:66–72.
- Arnett GW, Jelic JS, Kim J, Cummings DR. Soft tissue cephalometric analysis: diagnosis and treatment planning of dentofacial deformity. *Am J Orthod Dentofac Orthop.* 1999;116:239–53.
- Bear S, Priest J. Sleep apnea syndrome: correction with surgical advancement of the mandible. *J Oral Surg.* 1980;38:543–9.
- Spire J, Kuo P, Campbell N. Maxillo-facial surgical approach: an introduction and review of mandibular advancement. *Bull Eur Physiopathol Respir.* 1983; 19:604–6.
- Powell N, Guilleminault C, Riley R, Smith L. Mandibular advancement and obstructive sleep apnea syndrome. *Bull Eur Physiopathol Respir.* 1983;19: 607–10.
- Riley RW, Powell NB, Guilleminault C, Nino-Murcia G. Maxillary, mandibular, and hyoid advancement: an alternative to tracheostomy in obstructive sleep apnea syndrome. *Otolaryngol Head Neck Surg.* 1986;94:584–8.
- Jamieson A, Guilleminault C, Partinen M, Quera-Salva MA. Obstructive sleep apneic patients have craniomandibular abnormalities. *Sleep Med.* 1986;9: 469–77.
- Pirklbauer K, Russmueller G, Stiebellehner L, Nell C, Sinko K, Millesi G, et al. Maxillomandibular advancement for treatment of obstructive sleep apnea syndrome: A Systematic Review. *J Oral Maxillofac Surg.* 2011;69:165–76.
- Li KK, Riley RW, Powell NB, Guilleminault C. Patient's perception of the facial appearance after maxillomandibular advancement for obstructive sleep apnea syndrome. *J Oral Maxillofac Surg.* 2001;69:165–76.
- Van Loon B, Van Heerbeek N, Bierenbroodspot F, Verhamme L, Xi T, de Koning J, et al. Three-dimensional changes in nose and upper lip volume after orthognathic surgery. *Int J Oral Maxillofac Surg.* 2015;44:83–9.
- Louis PJ, Austin RB, Waite PD, Mathews CS. Soft tissue changes of the upper lip associated with maxillary advancement in obstructive sleep apnea patients. *J Oral Maxillofac Surg.* 2001;59:151–6.
- Maal TJ, de Koning MJ, Plooi J, Verhamme LM, Rangel FA, Bergé SJ, et al. One year postoperative hard and soft tissue volumetric changes after a BSSO mandibular advancement. *Int J Oral Maxillofac Surg.* 2012;41:1137–45.
- Li KK. Maxillomandibular advancement for obstructive sleep apnea. *J Oral Maxillofac Surg.* 2011;69:687–94.
- Broadbent BH. A new X-ray technique and its application to orthodontia. *Angle Orthod.* 1931;1:45–66.
- Kuvat SV, Güven E, Hocaoglu E, Basaran K, Marsan G, Cura N, et al. Body fat composition and weight changes after double-jaw osteotomy. *J Craniofac Surg.* 2010;21:1516–8.
- Schendel SA, Williamson LW. Muscle reorientation following superior repositioning of the maxilla. *J Oral Maxillofac Surg.* 1983;41:235–40.
- Rosen HM. Lip-nasal aesthetics following Le Fort I osteotomy. *Plast Reconstr Surg.* 1988;81:171–82.
- Arnett GW, Bergman RT. Facial keys to orthodontic diagnosis and treatment planning—part II. *Am J Orthod Dentofac Orthop.* 1993;103:395–411.