

Case Study

Open Access

## Temporary ectropion therapy by adhesive taping: a case study

Thomas Schrom\*<sup>1</sup> and Anke Habermann<sup>2</sup>

Address: <sup>1</sup>Department of Oto-Rhino-Laryngology, Helios Clinics Bad Saarow, Germany and <sup>2</sup>Department of Ophthalmology, Martin-Luther-University Halle-Wittenberg, Germany

Email: Thomas Schrom\* - thomas.schrom@gmx.de; Anke Habermann - anke.habermann@medizin.uni-halle.de

\* Corresponding author

Published: 21 July 2008

Received: 10 January 2008

Head & Face Medicine 2008, 4:12 doi:10.1186/1746-160X-4-12

Accepted: 21 July 2008

This article is available from: <http://www.head-face-med.com/content/4/1/12>

© 2008 Schrom and Habermann; licensee BioMed Central Ltd.

This is an Open Access article distributed under the terms of the Creative Commons Attribution License (<http://creativecommons.org/licenses/by/2.0>), which permits unrestricted use, distribution, and reproduction in any medium, provided the original work is properly cited.

### Abstract

**Introduction:** Various surgical procedures are available to correct paralytic ectropion, which are applied in irreversible facial paresis. Problems occur when facial paresis has an unclear prognosis, since surgery of the lower eyelid is usually irreversible. We propose a simple method to correct temporary ectropion in facial palsy by applying an adhesive strip.

**Patients and methods:** Ten patients with peripheral facial paresis and paralytic ectropion were treated with an adhesive strip to correct paralytic ectropion. We used "Steri-Strips" (45 × 6.0 mm), which were taped on the carefully cleaned skin of the lower eyelid and of the adjacent zygomatic region until the prognosis of the paresis was clarified. In addition to the examiner's evaluation of the lower lacrimal point in the lacrimal lake, subjective improvement of the symptoms was assessed using a visual analogue scale (VAS, 1–10).

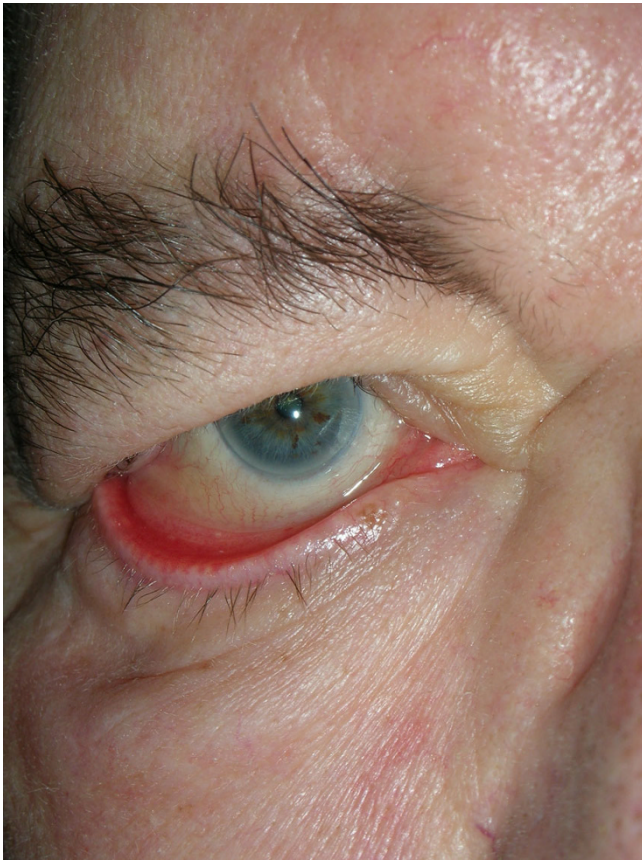**Results:** 9 patients reported a clear improvement of the symptoms after adhesive taping. There was a clear regression of tearing (VAS (median) = 8; 1 = no improvement, 10 = very good improvement), the cosmetic impairment of the adhesive tape was low (VAS (median) = 2.5; 1 = no impairment, 10 = severe impairment) and most of the patients found the use of the adhesive strip helpful. There was slight reddening of the skin in one case and well tolerated by the facial skin in the other cases.

**Conclusion:** The cause and location of facial nerve damage are decisive for the type of surgical therapy. In potentially reversible facial paresis, procedures should be used that are easily performed and above all reversible without complications. Until a reliable prognosis of the paresis can be made, adhesive taping is suited for the temporary treatment of paralytic ectropion. Adhesive taping is simple and can be performed by the patient.

### Introduction

Functional symptoms in peripheral facial paresis are especially due to the malfunction of both facial sphincter systems, the orbicularis oris and the orbicularis oculi muscle. A paretic orbicularis oculi muscle causes clinically visible lagophthalmos that can lead to varying degrees of keratopathy and thus to the loss of vision. Drooping of the eye-

brow, secondary dermato- or blepharochalasis of the upper lid and paralytic ectropion can also result in addition to lagophthalmos [1,2]. In paralytic ectropion, the nasolacrimal system is considerably impaired by the migration of the lacrimal point out of the lacrimal lake. Closure of the eyelid is normally a complex process. It begins with the lowering of the upper eyelid in the vertical



**Figure 1**  
**Ectropion in facial palsy.**

direction and makes short rapid horizontal movements in the medial direction. The lower lid, on the other hand, is pushed up and moved more strongly in the medial direction, in which the lid opening is shortened by 1 to 2 mm. The medial movement of the lids promotes the locomotion of the lacrimal fluid to the lacrimal lake, the lacrimal point and lacrimal canal and acts as a suction and force pump. The malfunction of the orbicularis oculi muscle in peripheral facial paresis can lead to both lagophthalmos with the risk of corneal desiccation and to a sensory disorder of the nasolacrimal system caused by the loss of the lacrimal pump.

The cause, location and prognosis of facial nerve damage are decisive for the type of surgical rehabilitation [3], although the surgical indication should be carefully made in the case of reversible paresis. Moreover, methods that are simple and reversible without complications should be used [4]. While different reversible surgical methods (including implants) exist for correcting lagophthalmos [5], the situation in the lower lid is considerably more difficult. A number of different surgical procedures are available for eliminating paralytic ectropion [2,6-9]. Common

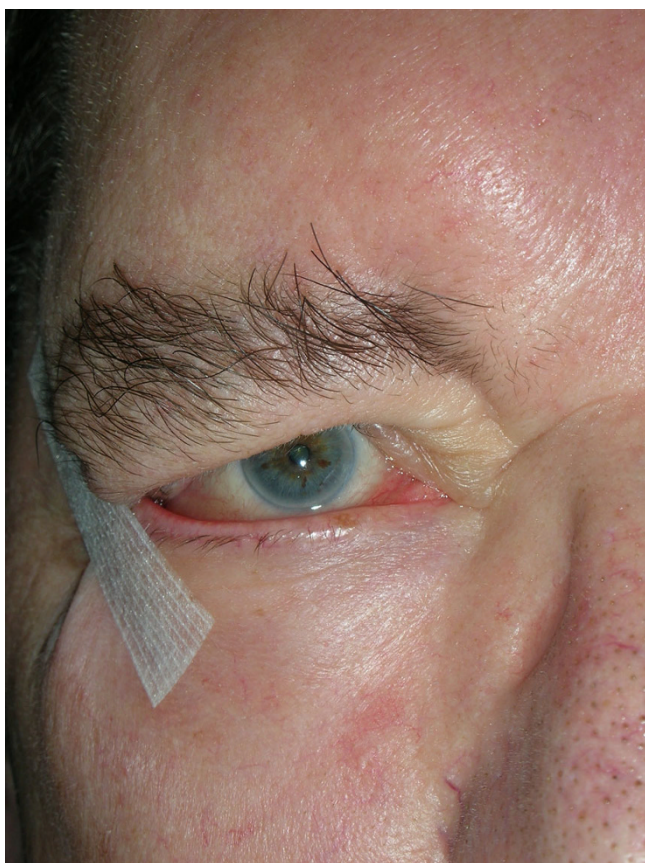methods include blepharorrhaphy (either medial or lateral depending on the finding), canthoplasty, lateral bridle grafts, and different types of tarsus excision [7]. The above-mentioned methods result in a horizontal lifting of the lower lid by an irreversible shortening of the eyelid. Furthermore, bridle grafts from the temporal muscle or alloplastic material [10] and augmentation of the lower lid tarsus with cartilage or alloplastic materials (e.g. porous polyethylene) are also used to lift the lower lid edge [2,11]. Except for the transfer of the temporal muscle, the other procedures are of a purely static nature and ultimately serve to bring the lower lid closer to the bulb and to relocate the lower lacrimal point in the lacrimal lake. Surgical correction of the lost suction and force pump of the lid has thus far not been possible.

There have hardly been any descriptions in the literature of conservative treatment procedures for correcting paralytic ectropion. One possible method is temporary correction by taping the lower lid to the adjacent zygomatic region with adhesive strips to invert the lower lacrimal point into the lacrimal lake. Adhesive strips have only been used in individual cases to correct lagophthalmos, entropion or ptosis of the eyebrow [12-15]. There have thus far been no systematic examinations of the correction of paralytic ectropion in a patient population for acceptance of this procedure as a conservative treatment method.

### Patients and methods

In a total of 10 patients suffering from peripheral facial paresis with resultant lagophthalmos and ectropion, taping of the lower lid to the adjacent zygomatic region with adhesive strips was performed either until the nerve completely recovered or final surgery of the ectropion. The patient population consisted of 5 females and 5 males with a mean age of 69.3 years. Facial paralysis resulted after resection of an acoustic neurinoma in 4 cases and after resection of a parotid tumor, temporal bone fracture, cholesteatoma and 3 cases of zoster oticus. The mean follow-up time was 3 months. Fig. 1 shows paralytic lower lid ectropion and fig. 2 the findings after adhesive strip taping. Steri-strips (45 × 6.0 mm) were attached between the lower lid and adjacent zygomatic region.

The pretherapeutic examination of ectropion includes an evaluation of the position of the lower lid in relation to the eyeball, horizontal palpebral fissure and lower lid tension. Lower lid tension can be assessed with the so-called snap test and distraction test. In the snap test the lower lid is pulled down then released so it can rebound. A lid that has not previously been operated on should return to its original anatomical position within one or two seconds. A delayed reaction is a sign of a loss of elasticity. In the distraction test, the lower lid is held between two fingers and

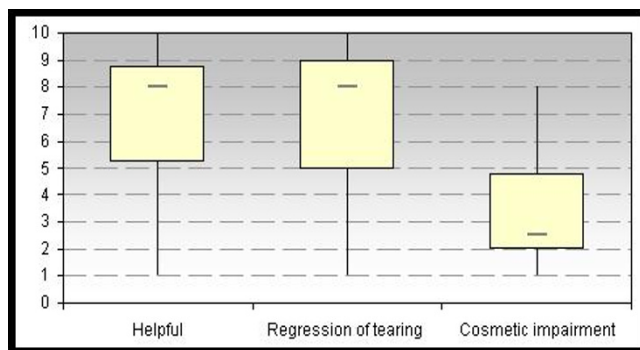


**Figure 2**  
Ectropion corrected by applying adhesive tape.

gently pulled in the ventral direction. Lifting of the lower lid from the eyeball by more than 8 mm is considered pathological and is pathognomonic for atonia of the lower lid. In addition to the evaluation of the lower lacrimal point in the lacrimal lake, the patient makes a subjective assessment using a visual analog scale (VAS 1–10). The patient can rate the reduction in tearing (1 = no improvement, 10 = excellent improvement), cosmetic impairment (1 = no impairment, 10 = considerable impairment) and practicability (1 = not helpful, 10 = very helpful). In all patients, a lid implant (platinum chain) was pretarsally implanted to correct the paralytic lagophthalmos.

**Results**

After fixation of the adhesive strips, inversion of the lower lacrimal point into the lacrimal lake was observed in all patients. Nine patients reported a clear improvement in their symptoms after application of the adhesive tape. There was a clear reduction in tearing (VAS (median) = 8; 1 = no improvement, 10 = excellent improvement), little cosmetic impairment (VAS (median) = 2.5; 1 = no impair-



**Figure 3**  
Results of the visual analog scales.

ment, 10 = considerable impairment) and most patient found the adhesive bridle to be helpful (VAS (median) = 8; 1 = not helpful, 10 = very helpful). In the meantime, 5 patients use the adhesive tape daily and 4 patients occasionally depending on the situation. Fig. 3 illustrates the results of the visual analog scales.

In one case, there was slight reddening of the skin, which completely healed after the adhesive bridle was no longer used. No other complications were observed.

**Discussion**

The causes of ectropion may be age-related, paralytic, cicatricial, mechanical or hereditary. It may also be caused by tumor infiltration in the infra-orbital region. Depending on the cause, different surgical procedures are used to correct the ectropion [16], which include in the most cases a shortening of the palpebral fissure for horizontal lifting of the lower lid or the augmentation of the lower lid tarsus with cartilage or alloplastic materials (e.g. porous polyethylene) [7,11]. Since the reversibility of these procedures can be problematic, the indication to use the above methods should be carefully made in potentially reversible paresis [4]. The clinical course should be confirmed with electrophysiological tests in doubtful cases and surgical intervention initially postponed in the case of unclear findings.

In addition to lagophthalmos, manifestations of facial paresis around the eye include a dropping eyebrow, secondary dermato- or blepharochalasis of the upper lid and ectropion [1,2], in which the paralytic ectropion mainly affects the lateral parts of the lower lid in most cases [10,17]. Taping with adhesive strips has been described as a conservative therapeutic approach for both lagophthalmos and ptosis of the eyebrow [12-14]. Our study has shown that taping the lower lid to the adjacent zygomatic region with adhesive strips leads to a static lifting of the lower lid and to inversion of the lower lacrimal point into



the lacrimal lake. This considerably reduced the patients' subjective symptoms. The method is thus suitable for both temporary conservative therapy and for patients who decline further surgery. The use of skin-colored Steri-strips (45 × 6.0 mm) reduced cosmetic impairment even further. The advantages of the Steri-strips are good skin tolerance, wide availability in most hospitals and the low cost. Their application is easy and can be performed by the patient, if necessary.

### Conclusion

The patients' subjective well-being could be improved overall using adhesive strips. The correction of paralytic ectropion by adhesive strips is especially suited as a temporary, conservative procedure. The method is simple, inexpensive and can be performed by the patient.

### Competing interests

The authors declare that they have no competing interests.

### Authors' contributions

TS conceived the study and drafted the manuscript. AH participated in the design of the study, acquisition of the data and statistical analysis. All authors read and approved the final manuscript.

### References

- Levine R: **Reanimation of paralyzed eyelids.** *Facial Plast Surg* 1992, **8(2)**:121-126.
- May M, Hoffmann D, Buerger G, Soll D: **Management of the paralyzed lower eyelid by implanting auricular cartilage.** *Arch Otolaryngol Head Neck Surg* 1990, **116(7)**:786-788.
- Jungehulsing M, Guntinas-Lichius O, Stennert E: **Rehabilitation in chronic facial paralysis.** *HNO* 2001, **49(5)**:418-426.
- Seiff S, Chang J: **The staged management of ophthalmic complications of facial nerve palsy.** *Ophthalmic Plast Reconstr Surg* 1993, **9**:241-249.
- Schrom T, Habermann A, Wernecke K, Scherer H: **Implantation von Lidgewichten zur Therapie des Lagophthalmus.** *Ophthalmologie* 2005, **102(12)**:1186-1192.
- Andersen J: **Surgical correction of lagophthalmos, complicated by paralytic ectropion.** *Br J Plast Surg* 1976, **29**:234-237.
- Fedok F, Ferraro R: **Restoration of lower eyelid support in facial paralysis.** *Facial Plast Surg* 2000, **16(4)**:337-343.
- Lisman R, Smith B, Baker D, Arthurs B: **Efficacy of surgical treatment for paralytic ectropion.** *Ophthalmology* 1987, **94(6)**:671-681.
- Wesley R, Collins J: **McCord procedure for ectropion repair.** *Arch Otolaryngol* 1983, **109**:319-322.
- Hayashi A, Maruyama Y, Okada E, Ogino A: **Use of a suture anchor for correction of ectropion in facial paralysis.** *Plast Reconstr Surg* 2005, **115(1)**:234-239.
- Tan J, Olver J, Wright M, Maini R, Neoh C, Dickinson A: **The use of porous polyethylene (Medpor) lower eyelid spacers in lid heightening and stabilisation.** *Brit J Ophthalmol* 2004, **88(9)**:1197-1200.
- Fernandez E, Pallini R, Maira G: **Alternative to tarsorrhaphy in peripheral facial nerve palsy with expectation of functional recovery. Technical note.** *J Neurosurg* 1984, **61(2)**:405-406.
- Imran D, Javaid M, Lewis D: **Approximation of the eyelids using Steri-Strips for effective eye closure.** *Plast Reconstr Surg* 2004, **113(5)**:1518-1519.
- Imran D, James M, James N: **Stick it up: a temporary aid to improve unilateral brow ptosis.** *Plast Reconstr Surg* 2004, **113(6)**:1891-1892.
- Irvine S, Francis I, Bishop A, Baxter J: **The entropion patch: a method of temporarily correcting involutional entropion with adhesive tape.** *Ophthalmic Surg* 1994, **25(9)**:604-606.
- Liebau J, Schulz A, Arens A, Tilkorn H, Schwipper V: **Management of lower lid ectropion.** *Dermatol Surg* 2006, **32(8)**:1050-1056.
- Papalkar D, Francis I, Wilcsek G: **Correction of ectropion in facial paralysis.** *Plast Reconstr Surg* 2006, **117(2)**:677.

Publish with **BioMed Central** and every scientist can read your work free of charge

"BioMed Central will be the most significant development for disseminating the results of biomedical research in our lifetime."

Sir Paul Nurse, Cancer Research UK

Your research papers will be:

- available free of charge to the entire biomedical community
- peer reviewed and published immediately upon acceptance
- cited in PubMed and archived on PubMed Central
- yours — you keep the copyright

Submit your manuscript here:  
[http://www.biomedcentral.com/info/publishing\\_adv.asp](http://www.biomedcentral.com/info/publishing_adv.asp)

